


AJCC 8th Edition Staging

Head & Neck Staging

Donna M. Gress, RHIT, CTR
Technical Editor, AJCC Cancer Staging Manual
First Author, Chapter 1: Principles of Cancer Staging



AJCC
American Joint Committee on Cancer
Validating science. Improving patient care.

No materials in this presentation may be repurposed in print or online without the express written permission of the American Joint Committee on Cancer. Permission requests may be submitted at cancerstaging.org.

This webinar is sponsored by

The Centers for Disease Control and Prevention

Supported by the Cooperative Agreement Number DP13-1310


The findings and conclusions in this report are those of the authors and do not necessarily represent the official position of the Centers for Disease Control and Prevention.

National Center for Chronic Disease Prevention and Health Promotion
National Program of Cancer Registries



Learning Objectives


- Explain cervical nodes and unknown primary tumors criteria
- Examine importance of EBV and HPV-mediated (p16+)
- Identify changes oral cavity chapter
- Analyze extranodal extension (ENE)



3 Copyright © 2018 AJCC. All Rights Reserved


Learning Assessments

- Testing effect or retrieval practice
 - Testing yourself on idea or concept to help you remember it
- Many experts have agreed for centuries
 - Act of retrieving info over and over, makes it retrievable when needed
 - Aristotle: exercise in repeatedly recalling strengthens memory
- Why retrieval/quizzing slows forgetting, helps remembering
 - Memory is dynamic (keeps changing), retrieval helps it change
 - Test often for better results
- Quizzes
 - Pretest as part of registration
 - Quiz during lecture
 - Posttest emailed weeks later to assess retention
 - Also assesses clarity of instruction and instructor




4 Copyright © 2018 AJCC. All Rights Reserved

Cervical Lymph Nodes and Unknown Primary Tumors of H&N – Chapter 6



Cervical Nodes & Unknown Primary Criteria

- Neck nodes are involved
- With/without distant mets, **not** distant mets without nodes
- **Not** EBV-related
- **Not** HPV-related
- Primary tumor **not** identified
 - Cannot presume primary site
 - Cannot pick which H&N chapter to use
 - Physician may **not** choose primary site or H&N chapter



6 Copyright © 2018 AJCC. All Rights Reserved

Unknown Primary

- T0 assigned for unknown primary in H&N
- Do **NOT** use H&N site chapters if no primary identified
- T0 **removed** from H&N site chapters to **prevent** their use
- Exceptions
 - Nasopharynx (EBV)
 - Oropharynx p16+ (HPV)
 - Salivary glands (unique histology)

7 Copyright © 2018 AJCC. All Rights Reserved

Chapter Selection for HPV & EBV Results

| AJCC Chapter Selection | EBV | | |
|------------------------|-------------|----------------|----------------|
| | positive | negative | unknown |
| HPV positive | nasopharynx | oropharynx | oropharynx |
| HPV negative | nasopharynx | cervical nodes | cervical nodes |
| HPV unknown | nasopharynx | cervical nodes | cervical nodes |

8 Copyright © 2018 AJCC. All Rights Reserved

Neck Nodes with Unknown H&N Primary

7th Edition

- Staging based on nodal involvement
- Case distribution by primary site not based on scientific evidence
- Physicians guessed at primary site, no evidence
- C76.0 not used, unstageable

AJCC 7th TO N+

- Lip & Oral Cavity
- Pharynx
- Larynx
- Nasal Cavity & Sinus
- Salivary Glands

8th Edition

- Staging based on nodal involvement
- Case distribution by primary site based on scientific evidence
- Choose based on EBV or HPV, all similar cases grouped together
- C76.0 indicates Cervical Nodes Chapter

AJCC 8th TO N+

- Cervical Nodes and Unknown Primary of H&N C76.0
- EBV+ Nasopharynx C11.9
- HPV+ Oropharynx C10.9


9 Copyright © 2018 AJCC. All Rights Reserved

Prognostic Stage Groups

- Metastatic cervical adenopathy & unknown primary tumor
 - *Except* for EBV-related and HPV-related tumors

| When T is... | And N is... | And M is... | Then the stage group is... |
|--------------|-------------|-------------|----------------------------|
| T0 | N1 | M0 | III |
| T0 | N2 | M0 | IVA |
| T0 | N3 | M0 | IVB |
| T0 | Any N | M1 | IVC |


10 Copyright © 2018 AJCC. All Rights Reserved.



Scenario

- Patient had 2cm submental node. Nodal bx showed G3 non-keratinizing squamous cell ca. No primary lesion identified. EBV and HPV testing not done. Physician states probably floor of mouth primary.
- Use Cervical Nodes & Unknown Primary chapter
 - Neck nodes involved
 - Primary tumor not found/identified
 - Physician assumptions are **NOT** used to choose AJCC chapter
- cT0 cN1 cM0 clinical stage III
- Code topography to C76.0 per SSDI Task Force
 - Registry schema discriminator uses C76.0 to select Chapter 6
 - SSDI CAnswer Forum for questions on schema discriminator

11 Copyright © 2018 AJCC. All Rights Reserved.




EBV & HPV-Mediated



HPV-Mediated


- HR-HPV associated cancer
 - Younger, healthier individuals
 - Little or no tobacco exposure
 - Much better survival than traditional tobacco-associated CA
- Testing
 - High Risk-HPV DNA
 - More expensive and less available
 - Technically more variability with interpretation
 - p16
 - Inexpensive and near universal availability
 - Easily standardized interpretation
 - Surrogate for disease



13 Copyright © 2018 AJCC. All Rights Reserved.

p16


- What is p16
 - Tumor suppressor protein
 - Also known as cyclin-dependent kinase inhibitor 2A
 - Biomarker overexpressed (produced) in response to HPV
- Testing performed by immunohistochemistry (IHC)
- p16 overexpression
 - Highly correlated with HR-HPV
 - HR-HPV include HPV 16, 18, 31, 33, 45, 52, 58 and others
- Do not confuse p16 with HPV 16
- **Must** be p16+ to use HPV-mediated chapter



14 Copyright © 2018 AJCC. All Rights Reserved.

HPV-Mediated (p16+) Oropharynx (Ch 10)

- Conflicting test results, use Ch 10 (p16+) or Ch 11 (p16-)
 - Q: p16 strongly positive, HPV negative by ISH for some subtypes
 - A: p16 is decider, other high risk HPV not tested in ISH
- Synonyms for HPV-mediated cancers in Table 10.1
 - Q: Does p16 negative non-keratinizing OPSCC use Ch 10?
 - A: Absolute that p16 must be positive for Ch 10
unknown or negative staged with Ch 11 p16- oropharynx
cannot use histology as deciding factor




15 Copyright © 2018 AJCC. All Rights Reserved.

EBV-related Unknown Primary

- Epstein-Barr virus-associated nasopharynx (EBV-related)
- Epstein-Barr encoding region (EBER)
 - In situ hybridization (ISH) testing method
 - Identifies copies of EBERs present in latently infected cells
 - Detects Epstein-Barr virus
 - Suggests nasopharyngeal origin
- EBER required for staging cervical nodes & unknown primary
 - EBER- SCC staged in Cervical Node Chapter as T0 N-appropriate
 - EBER+ staged in Nasopharynx Chapter as T0 N-appropriate

| | |
|----|--|
| T0 | No tumor identified, but EBV-positive cervical node(s) involvement |
|----|--|


16 Copyright © 2018 AJCC. All Rights Reserved



Scenario

- Patient had 2cm submental node. Nodal bx showed poorly differentiated G3 squamous cell ca. No primary lesion identified. p16 positive, HPV ISH negative for HPV 16/18. Physician states probably floor of mouth primary.
- Use HPV-mediated (p16+) oropharyngeal chapter
 - p16+
 - HPV testing is not used, many more HR-HPV types
 - Neck nodes involved
 - Primary tumor not found/identified
 - Primary site is oropharynx
 - Physician assumptions are **NOT** used to choose AJCC chapter
 - AJCC grade 3 not assigned, no AJCC histologic grade even on primary site
- cT0 cN1 cM0 clinical stage I

17 Copyright © 2018 AJCC. All Rights Reserved



Oral Cavity

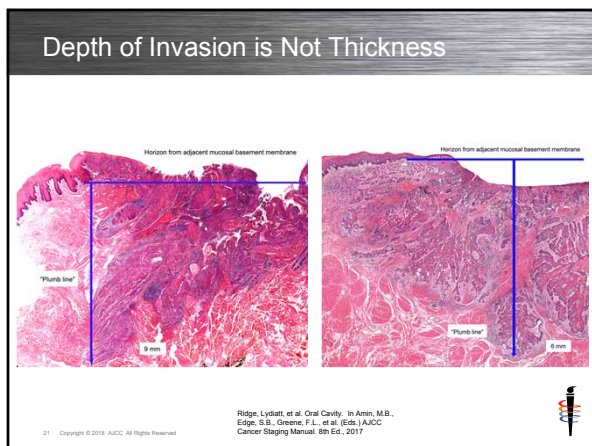


Oral Cavity Change Highlights

| Before Correction | After Correction |
|--|---|
| T2: Tumor ≤ 2 cm, DOI > 5 mm and ≤ 10 mm or tumor > 2 cm but ≤ 4 cm, DOI ≤ 10 mm | T2: Tumor ≤ 2 cm with DOI* > 5 mm or tumor > 2 cm and ≤ 4 cm with DOI* ≤ 10 mm |
| T3: Tumor > 4 cm or any tumor with DOI > 10 mm but ≤ 20mm | T3: Tumor > 2 cm and ≤ 4 cm with DOI* > 10 mm or tumor > 4 cm with DOI* ≤ 10 mm |
| T4a: Moderately advanced local disease Tumor invades adjacent structures only (e.g., through cortical bone of the mandible or maxilla, or involves the maxillary sinus or skin of the face) or extensive tumor with bilateral tongue involvement and/or DOI > 20 mm. | T4a: Moderately advanced local disease Tumor > 4 cm with DOI* > 10 mm or tumor invades adjacent structures only (e.g., through cortical bone of the mandible or maxilla or involves the maxillary sinus or skin of the face) |


19 Copyright © 2018 AJCC. All Rights Reserved.

- ### Oral Cavity Change Highlights
- Clinical and pathological depth of invasion (DOI)
 - Now used in conjunction with tumor size
 - To determine T category
 - DOI is **NOT** tumor thickness
 - DOI supersedes muscle invasion
 - Any clinical ENE(+) will be designated cN3b
 - Pathological ENE(+)
 - Will increase pN category by one full category
 - Example: from pN1 to pN2, or from pN2 to pN3
- 20 Copyright © 2018 AJCC. All Rights Reserved.



Scenario

- Patient had 2cm submental node. Nodal bx showed poorly differentiated G3 squamous cell ca. Floor of mouth lesion 3.5cm with DOI 6mm; bx G3 squamous cell ca.
- Use oral cavity chapter
 - Neck nodes involved
 - Primary tumor identified in floor of mouth
 - Need tumor diameter and DOI
 - DOI based on palpation, physical symptoms, imaging
 - AJCC grade 3 assigned
- cT2 cN1 cM0 clinical stage III




22 Copyright © 2018 AJCC. All Rights Reserved

Extranodal Extension (ENE)



Extranodal Extension (ENE)

- ENE has profound effect on prognosis in head & neck
 - Evidence supports ENE as adverse prognostic factor
 - Most evidence from pathologic analysis of nodes
 - Pathology includes distinction between microscopic & major
- Inclusion of ENE in N category
 - Unknown Primary Cervical Nodes
 - Oral Cavity
 - Salivary Gland
 - p16- Oropharynx and Hypopharynx
 - Nasal Cavity and Paranasal Sinus
 - Larynx
 - Skin
- **NOT** in p16+ Oropharynx, Nasopharynx, Melanoma H&N




24 Copyright © 2018 AJCC. All Rights Reserved

Clinical Staging

- Stringent criteria *required* to permit ENE(+) diagnosis
- Unambiguous evidence of gross ENE on clinical exam
 - Invasion of skin
 - Infiltration of musculature or dense tethering to adjacent structures
 - Nerve invasion with dysfunction
 - Cranial nerve
 - Brachial plexus
 - Sympathetic trunk
 - Phrenic nerve
 - Supported by strong radiographic evidence
- Radiographic evidence *alone* is insufficient
- If any doubt or ambiguity, assign ENE(-)


25 Copyright © 2018 AJCC. All Rights Reserved



Pathological Staging

- Clearly defined pathological ENE(+) based on
 - Tumor present within confines of node and
 - Extending through node capsule
 - Into surrounding connective tissue
 - With or without associated stromal reaction
- ENE(+) may be classified as
 - ENE_{mi} for microscopic ENE ≤2 mm beyond node capsule
 - ENE_{ma} for major ENE >2 mm beyond node capsule microscopically
 - ENE_{ma} apparent to naked eye at dissection
- If any doubt or ambiguity, assign ENE(-)


26 Copyright © 2018 AJCC. All Rights Reserved



ENE Reminder


- Terminology for extension outside lymph nodes
 - ENE is preferred wording – extranodal extension
 - Not extracapsular spread/extension
 - Not extranodal spread/involvement
- Clinical N category
 - Any ENE+ is N3b
- Pathological N category
 - ENE+ increases N category by one full category

27 Copyright © 2018 AJCC. All Rights Reserved




Scenario

- Patient had 2cm submental node. Decreased salivation & taste, tongue movement, diminished gag reflex. Nodal bx showed poorly differentiated G3 squamous cell ca. Floor of mouth lesion 3.5cm with DOI 6mm; bx G3 squamous cell ca.
- Use oral cavity chapter
 - Neck nodes involved
 - ENE(+) with cranial nerve invasion with dysfunction
 - Dysfunction: decreased sense of taste & salivation, diminished gag reflex (glossopharyngeal CN IX); tongue (hypoglossal CN XII)
 - Primary tumor identified in floor of mouth
 - Need tumor diameter and DOI
 - DOI based on palpation, physical symptoms, imaging
 - AJCC grade 3 assigned
- cT2 cN3b cM0 clinical stage IVB





28 Copyright © 2018 AJCC. All Rights Reserved

Information and Questions on AJCC Staging



AJCC Web site



- <https://cancerstaging.org>
- Ordering information
 - Cancerstaging.net
- General information
 - Education
 - Articles
 - Updates



30 Copyright © 2018 AJCC. All Rights Reserved

CAnswer Forum

- Submit questions to AJCC Forum
 - NEW 8th Edition Forum
 - 7th Edition Forum will remain
 - Located within CAnswer Forum
 - Provides information for all
 - Allows tracking for educational purposes
- <http://cancerbulletin.facs.org/forums/>



31 Copyright © 2018 AJCC. All Rights Reserved

Quiz




Summary



Summary


- Comprehend cervical nodes/unknown primary tumors criteria
- Interpret role of EBV and HPV-mediated (p16+)
- Identify extranodal extension (ENE) criteria
- Examine changes in oral cavity head & neck staging




45 Copyright © 2018 AJCC. All Rights Reserved.

Thank you

Donna M. Gress, RHIT, CTR
Technical Editor AJCC Cancer Staging Manual
First Author, Chapter 1: Principles of Cancer Staging



AJCC
American Joint Committee on Cancer
Validating science. Improving patient care.



633 N. Saint Clair, Suite 2400, Chicago, IL 60611-3295
cancerstaging.org

No materials in this presentation may be repurposed in print or online without the express written permission of the American Joint Committee on Cancer. Permission requests may be submitted at cancerstaging.org.

This webinar is sponsored by

The Centers for Disease Control and Prevention

Supported by the Cooperative Agreement Number DP13-1310

The findings and conclusions in this report are those of the authors and do not necessarily represent the official position of the Centers for Disease Control and Prevention.



National Center for Chronic Disease Prevention and Health Promotion
National Program of Cancer Registries
